

Difficult glottis: Diagnostic dilemma in view of the clinical presentation

Authors' Contribution:

A – Study Design
B – Data Collection
C – Statistical Analysis
D – Data Interpretation
E – Manuscript Preparation
F – Literature Search
G – Funds Collection

Hanna Klimza^{1CEF}, Joanna Witkiewicz^{1CEF}, Joanna Jackowska^{1BD}, Małgorzata Wierzbicka^{1,2AEF}

¹Department of Otolaryngology, Head and Neck Surgery, and Laryngological Oncology, Medical University of Karol Marcinkowski, Poznan, Poland

²Institute of Human Genetics, Polish Academy of Sciences, Poznan, Poland

Article history: Received: 17.05.2023 Accepted: 19.06.2023 Published: 21.07.2023

ABSTRACT:

Introduction: The taxonomy of vocal fold lesions has been refined, and it serves as a common descriptive language for diagnosis, treatment algorithms, and reporting of outcomes. However, we observe rare cases when numerous pathologies overlap, resulting in an unclear and complicated clinical presentation of the glottis.

Aim: The aim of this paper is to present cases of overlapping etiopathological factors which poses a challenge when making a diagnosis and referring a patient for adequate treatment.

Material and method: The study presents different photographs of the glottis, including some unique and unusual images in which overlapping pathologies were captured. The photographs are accompanied by case descriptions, comments, and pathological analyses.

Results: Four selected photographs showed a bunch of exophytic growth lesions with foci of whitish plaques, covered by yellowish crusts, with thinned, reddened vocal folds presenting foci of leukoplakia. The study discussed possible causes of vocal folds edema, diffuse erythema, presence of crusts or exudate, whitish debris/plaques or development of leukoplakia, non-neoplastic ulceration, as well as injected and reddened mucous membrane. Chronic infectious laryngitis, idiopathic ulcerative laryngitis, and drug-induced laryngitis were also mentioned. The study also raised the issues concerning diabetics and patients treated with inhaled corticosteroids, including candidiasis and primary aspergillosis of the larynx.

Conclusions: To conclude, everyday clinical practice involves encountering cases of unclear onset and course, with complicated presentation of the glottis. Therefore, comprehensive history-taking and thorough investigation of systemic causes are of immense importance. Recommended management includes conducting the most meticulous differential diagnosis, implementing treatment for the most likely cause, and, whenever possible, refraining from biopsy in order to avoid permanent damage to vocal cords.

KEYWORDS:

biopsy, endoscopy, glottis, larynx

ABBREVIATIONS

HPV – human papillomavirus

HSV – high speed videoendoscopy

IgE – immunoglobulin E

IPCLs – intrapapillary capillary loops

IUL – idiopathic ulcerative laryngitis

LPR – laryngopharyngeal reflux

LVS – laryngovideoscopy

MRSA – methicillin-resistant *Staphylococcus aureus*

NBI – narrow band imaging

PPI – proton pump inhibitor

INTRODUCTION

The pathologies of the vocal folds and the corresponding images are well known, and the individual disease entities have been exhaustively described [1]. The underlying aetiologies for the devel-

opment of glottis pathology are long-term smoking and alcohol abuse, inhaled irritant substances, viral infections such as HPV, occupational hazards, nutritional deficiencies, systemic dehydration, vocal abuse or even phonotraumatic vocal fold lesions, chronic infections, hormonal disorders and laryngopharyngeal reflux disease [2–4]. Patients with vocal fold pathologies usually display hoarseness of the voice as the most common symptom and often the reason for referral to an ENT doctor.

Diagnosis of laryngeal diseases with accompanying voice disorders is established using laryngoscopy [2]. The past two decades have brought about major technological advancement in endoscopic methods, which has resulted in improved imagery resolution, contrast enhancement, magnification and special filters for better exposure of the vascular structure of the mucosa. Laryngovideoscopy (LVS) is a useful investigation adjunct, now improved by dynamic laryngeal imaging and high speed videoendoscopy (HSV) [5]. A form for collecting basic laryngostroboscopic findings which provides for the evaluation of the classical six param-

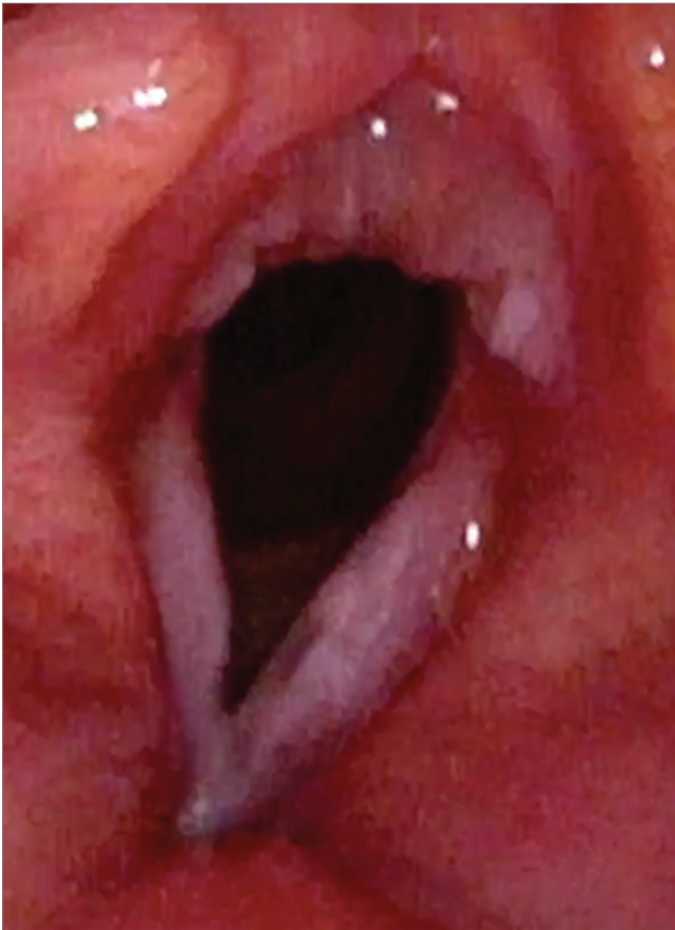

Fig. 1. The exophytic leukoplakia „cauliflower-like” in white light endoscopy.

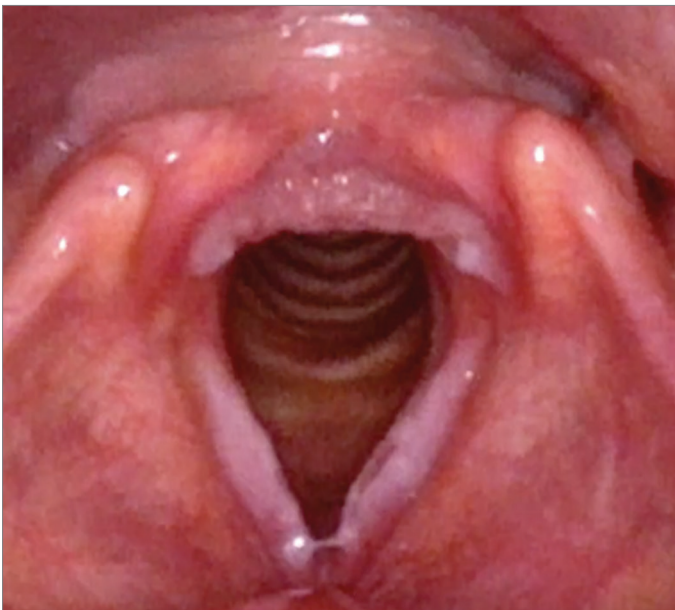

Fig. 2. The exophytic leukoplakia „cauliflower-like” in white light endoscopy.

ters has been codified by Hirano [6] and Dejonckere [7]. They are the symmetry and periodicity of glottic vibration, glottic closure, profile of vocal fold edge, amplitude of vocal fold vibration and mucosal wave. Six other parameters for an essential and complete laryngostroboscopic evaluation (supraglottic framework behaviour, seat of phonatory vibration, vocal fold morphology and motility,

level of vocal folds and stops of vocal fold mucosa vibration) have since been included later by Andrea Ricci-Maccarini [8]. Another adjunct to the larynx assessment is narrow band imaging (NBI), which allows for the identification of an abnormal vascular pattern within the mucosa, differentiation between benign and malignant lesions and assessment of the nature of lesions under the leukoplakia plaque [9].

The taxonomy of vocal fold lesions has been refined, and it serves as a common descriptive language for diagnosis, treatment algorithms and outcome reporting [1]. However, in rare cases, multiple pathologies overlap, making the picture of the glottis complicated and unclear. The aim of this paper is to present examples of overlapping aetiopathological factors, which make diagnosis and treatment selection a challenge.

MATERIAL AND METHOD

The material for this study consisted of images of the larynx, specifically the glottis, with a unique and unusual image of overlapping independent pathologies. These were images of glottises which had not been treated surgically, so there were no iatrogenic changes. The images are accompanied by a case description and commentary.

RESULTS

As seen in Fig. 1.–2., fiberoptic laryngoscopy showed bunches of “cauliflower-like” exophytic growth lesions, with foci of whitish plaques covered by yellowish crusts involving both vocal folds.

A 56-year-old female presented with a sudden onset of severe dyspnoea for one week. Her voice had been hoarse for ‘a long time’. She was asthmatic and was using an inhaled steroid (fluticasone 500 mcg bd) for 15 years. She had been treated for insulin-dependent diabetes for many decades, and her glycaemia remained well controlled. She also had a history of vocal abuse. She was treated with broad-spectrum antibiotics, repeatedly during the winter flu season, due to recurrent upper and lower respiratory tract infections.

Transoral laser microsurgery was performed, the vocal folds were cleaned under direct vision and biopsy samples were taken. Microscopic examination showed recurrent respiratory papillomatosis. The combination of three aetiopathogenetic factors – diabetes, the use of inhaled steroids and HPV infection – meant that the pathology was complex. It is noteworthy that she had never been diagnosed or treated for RRP before. An abundance of papillomas narrowed the glottis, though this would not indicate laryngeal dyspnea if not for the scabs of drying secretion that were difficult to expectorate, completely blocking the lumen of the larynx.

As seen in Fig. 3.–4., fiberoptic laryngoscopy showed thinned, reddened vocal folds with foci of leukoplakia. The vocal folds were stiff with an uneven free edge. There was no shortening of the glottis during phonation. The patient’s voice was very hoarse with periodic aphonia. Using narrowband imaging, proper, longitudinal vessels

with no intrapapillary capillary loops (IPCLs) were observed. This imaging was qualified as low-risk leukoplakia according to the NI 2019 classification (type II) (Fig. 3.–4.).

A 30-year-old man presented with a gradually deteriorating voice, initially tiresome after vocal effort, but after a few months permanently hoarse. The patient was a student, did not work in harmful conditions and did not report addictions or any other risk factors. The only abnormality from normal conditions were moderately intensified features of the LTR in the lower pharynx, but without a strong inflammatory reaction in the area of the upper larynx, arytenoids, aryepiglottic folds or epiglottis. At first, the patient received glucocorticosteroid inhalation and PPI treatment for one month, but without any results. Diagnostics had been extended to metabolic and allergic disorders, and the results showed an elevated titre of IgE antibodies. Therefore, the patient was administered antihistamine treatment for 2 months. Because significant improvement was observed in the control endoscopy, the invasive treatment (biopsy) was abandoned. The patient is under close supervision in our outpatient clinic.

DISCUSSION

We present a set of patients with a sudden, atypical onset of symptoms suggestive of acute laryngitis – dysphonia and hoarseness – but in whom the images of the glottis indicated long-term pathology and were difficult to interpret.

Oedema, diffuse erythema, crusting and exudate

Vocal fold oedema causing dysphonia is often a consequence of acute upper airway illness, allergy or voice overuse [10]. Thickened vocal fold epithelium, whitish debris or the leukoplakia, oedema and crusting upon laryngeal examination is found in chronic infectious laryngitis [11]. The symptoms – vocal roughness, vocal fatigue and decreased vocal endurance – can persist for over 3 months [12]. Chronic infectious laryngitis is defined as colonisation with bacteria not found in the previously characterised laryngeal microbiome of benign vocal fold lesions [13]. Cultures can be positive for methicillin-resistant *Staphylococcus aureus* (MRSA), *Streptococcus agalactiae*, *Moraxella catarrhalis* and *Corynebacterium accolens* [14, 15].

Historically, the routine use of antibiotics to treat chronic laryngitis has not been recommended [12] and otolaryngologists rarely treat chronic laryngitis with antibiotics as the first-line therapy, preferring to start with a proton pump inhibitor (PPI) to treat laryngopharyngeal reflux (LPR) as the presumed aetiology [16–18]. LPR probably plays a critical role in chronic bacterial laryngitis onset, but also constitutes the risk factors associated with the occurrence of larynx leukoplakia [19].

Chronic infectious laryngitis secondary to bacterial infection remains a poorly understood disease [20]. Chronic laryngitis in systemic lupus erythematosus may be caused by opportunistic organisms, such as tuberculous or fungal and *Staphylococcus aureus* infections [21]. In these rare cases, erythematous and oedematous bilateral vocal folds with a whitish lesion can be seen at the edge of the middle third, while videolaryngostroboscopic evaluation

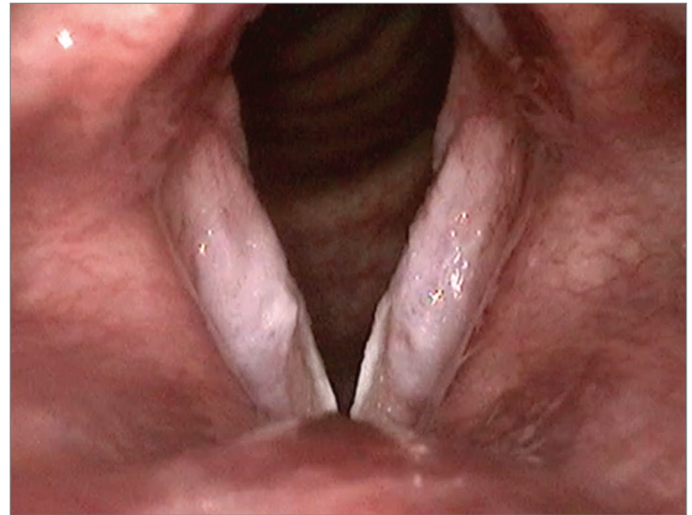


Fig. 3. The laryngeal leukoplakia in white light endoscopy.

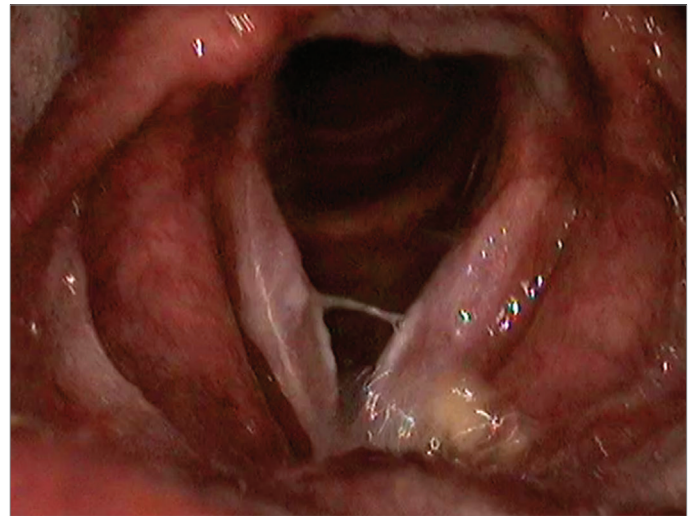


Fig. 4. The laryngeal leukoplakia in white light endoscopy.

shows severe asymmetry of the bilateral vocal folds, with severely reduced amplitude during phonation, aperiodic vibratory cycles and ‘always open,’ incomplete glottis closure [21]. Furthermore, in patients with representative autoimmune diseases, including systemic lupus, erythematosus and rheumatoid arthritis, bamboo node lesions can be found [22].

Non-neoplastic ulceration

Idiopathic ulcerative laryngitis (IUL) is a rare disorder characterised by ulceration in the mid-membranous portions of the vocal folds. The aetiology and optimal management of this condition are poorly understood [23]. Pill-induced laryngitis is another extremely rare phenomenon. While typically associated with bisphosphonates, this condition should be considered in any patient presenting with dysphonia and a history of pill aspiration, including iron supplements [24].

Injected, reddened mucous membrane

Injected, reddened mucous membrane is characteristic of recipients of inhaled corticosteroids. The frequent use of inhaled corticosteroids, the most effective therapeutic strategy for asthma

control, has been accompanied by concerns about their potential adverse effects in the oral cavity and pharynx, such as hoarseness, dysphonia, pharyngitis and cough reflex [25, 26]. Videostroboscopy shows 'injection' mucosa and increased mucus [27]. The rare but serious adverse effects of long-term steroid intake are laryngeal candidiasis [28] and primary laryngeal aspergillosis.

Isolated aspergillus laryngitis is casuistic, mainly occurring in an immunocompetent host [29]. It is often diagnosed after surgical excision or biopsy for a suspected premalignant or malignant pathology, though the thick keratosis layer may mimic the tumor. The most common involved site is the true vocal cords [30].

Superficial fungal infection of the mucous membranes, namely thrush, manifesting as whitish plaques isolated to the larynx, is neither widely reported nor well recognized clinically, and thus is often associated with ineffective treatment, delay in diagnosis and sometimes unnecessary surgical intervention. Possible causative factors include the use of systemic steroids, broad-spectrum antibiotics or inhaled steroids, as well as diabetes or neutropenia [31].

REFERENCES

- Naunheim M.R., Carroll T.L.: Benign vocal fold lesions: update on nomenclature, cause, diagnosis, and treatment. *Curr Opin Otolaryngol Head Neck Surg.*, 2017; 25(6): 453–458. doi: 10.1097/moo.0000000000000408.
- Anis M.M., Diaz J., Patel M., Lloyd A.T., Rosow D.E.: Glottic Keratosis: Significance and Identification of Laryngoscopic Findings. *OTO Open.*, 2021; 5(1): 2473974X21994743. doi: 10.1177/2473974X21994743.
- Mannelli G., Cecconi L., Gallo O.: Laryngeal preneoplastic lesions and cancer: challenging diagnosis. Qualitative literature review and meta-analysis. *Crit Rev Oncol Hematol.*, 2016; 106: 64–90. doi: 10.1016/j.critrevonc.2016.07.004.
- Venkatraman A., Hawkins J., McCain R., Duan C., Cannes do Nascimento N. et al.: The role of systemic dehydration in vocal fold healing: Preliminary findings. *Laryngoscope Investig Otolaryngol.*, 2022; 7(6): 1936–1942. doi: 10.1002/lio2.942.
- Malinowski J., Niebudek-Bogusz E., Just M., Morawska J., Racino A. et al.: Laryngeal High-Speed Videendoscopy with Laser Illumination: A Preliminary Report. *Otolaryngol Pol.*, 2021; 75(6): 1–10. doi: 10.5604/01.3001.0015.2575.
- Hirano M., McCormick, K. R.: Clinical Examination of Voice by Minoru Hirano. *The J Acoust Soc Am.*, 1986; 80(4): 1273–1273. doi: 10.1121/1.393788.
- Dejonckere P.H., Bradley P., Clemente P., Cornut G., Crevier-Buchman L. et al.: A basic protocol for functional assessment of voice pathology, especially for investigating the efficacy of (phonosurgical) treatments and evaluating new assessment techniques. Guideline elaborated by the Committee on Phoniatrics of the European Laryngological Society (ELS). *Eur Arch Otorhinolaryngol.*, 2001; 258(2): 77–82. doi: 10.1007/s004050000299.
- Ricci-Maccarini A., Bergamini G., Fustos R.: Proposal of a form for the collection of videolaryngostroboscopy basic findings. *Eur Arch Otorhinolaryngol.*, 2018; 275(7): 1927–1933. doi: 10.1007/s00405-018-4991-7.
- Klimza H., Jackowska J., Pietruszewska W., Rzepakowska A., Wierzbička M.: The Narrow Band Imaging as an essential complement to White Light Endoscopy in Recurrent Respiratory Papillomatosis diagnostics and follow-up process. *Otolaryngol Pol.*, 2021; 76(1): 1–5. doi: 10.5604/01.3001.0015.4540.
- Murphy Estes C., Chadwick K., Sadoughi B., Andreadis K., Sussman S. et al.: Performers' Perceptions of Vocal Function During Oral Steroid Treatment of Vocal Fold Edema. *Laryngoscope*, 2022; 132(12): 2434–2441. doi: 10.1002/lary.30072.
- Shah M.D., Klein A.M.: Methicillin-resistant and methicillin-sensitive *Staphylococcus aureus* laryngitis. *Laryngoscope*, 2012; 122(11): 2497–2502. doi: 10.1002/lary.23537.
- Schwartz S.R., Cohen S.M., Dailey S.H., Rosenfeld R.M., Deutsch E.S. et al.: Clinical practice guideline: hoarseness (dysphonia). *Otolaryngol Head Neck Surg.*, 141(3 Suppl 2): S1–S31. doi: 10.1016/j.otohns.2009.06.744.
- Thomas C.M., Jetté M.E., Clary M.S. Factors Associated With Infectious Laryngitis: A Retrospective Review of 15 Cases. *Ann Otol Rhinol Laryngol.*, 2017; 126(5): 388–395. doi: 10.1177/0003489417694911.
- Toyoshima H., Yamada H., Tanigawa M., Shigetoshi S.: Chronic Bacterial Laryngitis: A Diagnostic Pitfall for Clinicians. *Internal Medicine*, 2022; 61(4): 597–598. doi: 10.2169/internalmedicine.7796-21.
- Carpenter P.S., Kendall K.A.: MRSA chronic bacterial laryngitis: A growing problem. *Laryngoscope*, 2017; 128(4): 921–925. doi: 10.1002/lary.26955.
- Ford C.N.: GERD-Related Chronic Laryngitis: Pro. *Arch Otolaryngol Head Neck Surg.*, 2010; 136(9): 910. doi: 10.1001/archoto.2010.152.
- Yang Y., Wu H., Zhou J.: Efficacy of acid suppression therapy in gastroesophageal reflux disease-related chronic laryngitis. *Medicine*, 2016; 95(40): e4868. doi: 10.1097/md.0000000000004868.
- Vaezi M.F.: Benefit of Acid-Suppressive Therapy in Chronic Laryngitis: The Devil Is in the Details. *Clin Gastroenterol Hepatol.*, 2010; 8(9): 741–742. doi: 10.1016/j.cgh.2010.05.024.
- Lu G., Ding X., Xu W.: Association between Laryngopharyngeal Reflux and Vocal Fold Leukoplakia. *ORL.*, 2021; 83(3): 159–166. doi: 10.1159/000512527.
- Kinnari T.J., Lampikoski H., Hyyrynen T., Aarnisalo A.A.: Bacterial Biofilm Associated With Chronic Laryngitis. *Arch Otolaryngol Head Neck Surg.*, 2012; 138(5): 467. doi: 10.1001/archoto.2012.637.
- Mohd N., Baki M.M.: Glottic *Staphylococcus aureus* in a patient with systemic lupus erythematosus: videolaryngostroboscopic characteristics. *BMJ Case Rep.*, 2022; 15(2): e245840–e245840. doi: 10.1136/bcr-2021-245840.
- Meng X., Xu H.J., Li L.R., Zhao L.D.: Vocal cord lesions in representative autoimmune diseases. *Clin Rheumatol.*, 2023; 42(3): 929–939. doi: 10.1007/s10067-022-06411-9.
- Kim H.S., Moon J.W., Chung S.M., Lee J.H.: A Short-Term Investigation of Dysphonia in Asthmatic Patients Using Inhaled Budesonide. *J Voice.*, 2011; 25(1), 88–93. doi: 10.1016/j.jvoice.2009.07.003.
- Sethia R., Bishop R., Gordian-Arroyo A., Matrk L.: Iron Pill-Induced Chemical Laryngitis. *Ann Otol Rhinol Laryngol.*, 2022; 132(1): 91–94. doi: 10.1177/00034894221075115.
- Gallivan G.J., Gallivan K.H., Gallivan H.K.: Inhaled Corticosteroids: Hazardous Effects on Voice—An Update. *J of Voice.*, 2007; 21(1): 101–111. doi: 10.1016/j.jvoice.2005.09.003.

26. Pinto C.R., Almeida N.R., Marques T.S., Yamamura L.L.L., Costa L.A. et al.: Local adverse effects associated with the use of inhaled corticosteroids in patients with moderate or severe asthma. *J Bras Pneumol.*, 2013; 39(4): 409–417. doi: 10.1590/s1806-37132013000400003.
27. Kim C., Badash I., Gao W.Z., O'Dell K., Johns M.M.: Idiopathic Ulcerative Laryngitis: A National Survey of Academic Laryngologists. *J of Voice*, 2021; 35(6): 892–900. doi: 10.1016/j.jvoice.2020.04.009.
28. Wong K., Pace-Asciak P., Wu B., Morrison M.D.: Laryngeal candidiasis in the outpatient setting. *J Otolaryngol Head Neck Surg.*, 2009; 38(6): 624–627.
29. Saha A., Saha K., Chatterjee U.: Primary aspergillosis of vocal cord: Long-term inhalational steroid use can be the miscreant. *Biomed J.*, 2015; 38(6): 550–553. doi: 10.1016/j.bj.2015.09.001.
30. Sheth M.C., Paul R.R., Mathews S.S., Albert R.R.: Isolated Aspergillus Laryngitis: Spectrum, Management, and Review of Literature. *J of Voice.*, 2022; 36(6): 880.e13–880.e19. doi: 10.1016/j.jvoice.2020.09.009.
31. Sulica L.: Laryngeal Thrush. *Ann Otol Rhinol Laryngol.*, 2005; 114(5): 369–375. doi: 10.1177/000348940511400506.
32. Hamdan A., Jabbour J., Nassar J., Dahouk I., Azar S. T.: Vocal characteristics in patients with type 2 diabetes mellitus. *Eur Arch Otorhinolaryngol.*, 2012; 269(5): 1489–1495. doi: 10.1007/s00405-012-1933-7.
33. Abidin S.Z.Z., Kew T.Y., Azman M., Baki M.M.: Pseudomonas laryngeal perichondritis: unexpected diagnosis. *BMJ Case Rep.*, 2020; 13(12): e237129. doi: 10.1136/bcr-2020-237129.

Table of content: <https://otolaryngologypl.com/issue/15467> Tables: – Figures: 4 References: 33

Copyright: Copyright © 2023 Polish Society of Otorhinolaryngologists Head and Neck Surgeons. Published by Index Copernicus Sp. z o.o. All rights reserved.

Competing interests: The authors declare that they have no competing interests.



The content of the journal „Polish Society of Otorhinolaryngologists Head and Neck Surgeons” is circulated on the basis of the Open Access which means free and limitless access to scientific data.



This material is available under the Creative Commons – Attribution-NonCommercial 4.0 International (CC BY-NC 4.0). The full terms of this license are available on: <https://creativecommons.org/licenses/by-nc/4.0/legalcode>

Corresponding author: Hanna Klimza MD PhD; Department of Otolaryngology, Head and Neck Surgery, and Laryngological Oncology, Medical University of Karol Marcinkowski, Poznan; Przybyszewskiego street 49, 60-355 Poznan, Poland; E-mail: haniaklimza@gmail.com

Cite this article as: Klimza H., Witkiewicz J., Jackowska J., Wierzbička M.: Difficult glottis: Diagnostic dilemma in view of the clinical presentation; *Otolaryngol Pol* 2023; 77 (4): 53–57; DOI: 10.5604/01.3001.0053.7263